

CASE REPORT



Successful Removal of Acute and Organized SFA Thrombus in One Pass With the Pounce™ Thrombectomy System



Vince Weaver, MD
Vascular Surgeon
Vascular Specialty Center
Baton Rouge, LA

PATIENT PRESENTATION

A 45-year-old man presented with sudden left leg pain that had persisted for 1 week. The patient had a prior history of embolic and thrombotic events, including left common femoral artery (CFA) bifurcation embolus requiring open embolectomy and, 1 year later, percutaneous thrombectomy of the ostium of the superficial femoral artery (SFA).

DIAGNOSTIC FINDINGS

The initial angiogram showed new arterial thrombus in the mid to distal left SFA (**Figure One**). An ankle-brachial index of 0.6 was obtained. The patient was admitted and started on heparin before a left leg intervention with the Pounce™ Thrombectomy System was scheduled.

TREATMENT

A guidewire and support catheter traversed fairly easily through the occlusion. The Pounce system basket wire was deployed distal to the thrombus with the funnel catheter deployed proximal to the thrombus. The baskets were withdrawn into the funnel catheter and the whole system was removed, completing the first pass of the device (**Figure Two**). Although most of the thrombus that was removed was acute, organized thrombus was also found in the baskets of the Pounce system.

Diagnostic Angiogram

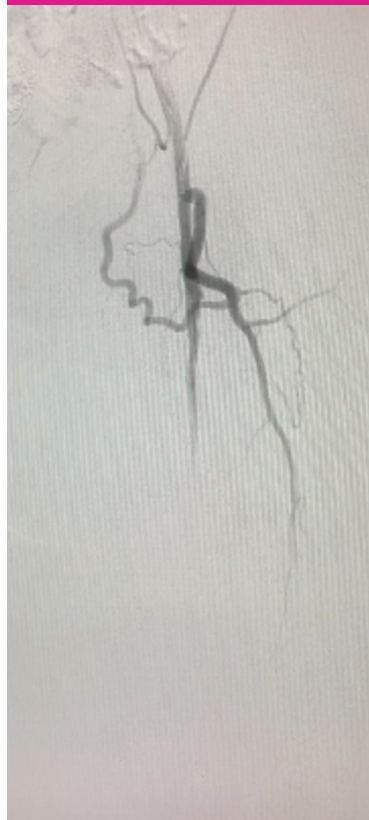

Figure One

Angiogram After One Pass with the Pounce™ System

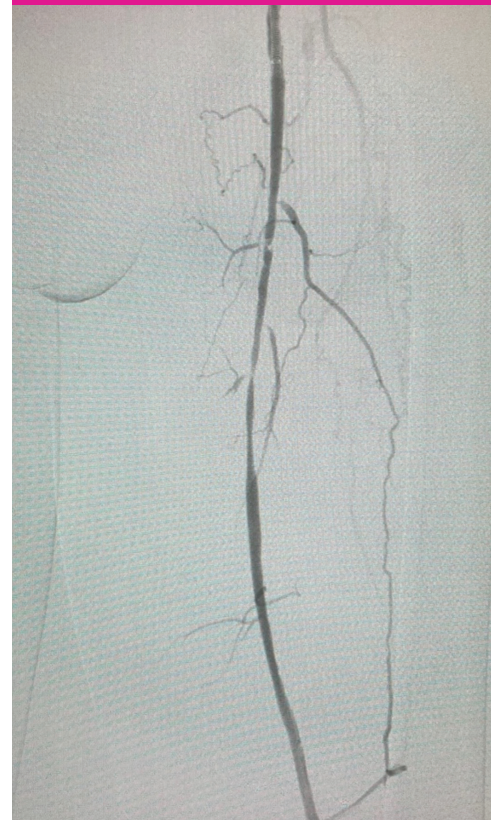


Figure Two

CASE REPORT



Dissection in the SFA
Due to Angioplasty

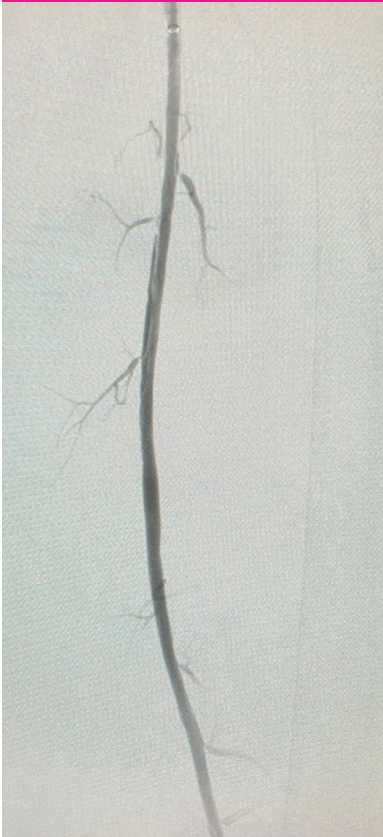

Figure Three

Final Angiogram
Showing Restoration
of Flow in the SFA




Figure Four

Balloon angioplasty was also performed to clear out the residual disease in the vessel. A dissection was observed due to the balloon angioplasty (**Figure Three**), and a 7 X 40 mm covered stent was placed in the dissected segment. The final angiogram showed full restoration of flow through the SFA (**Figure Four**).

POST PROCEDURE OUTCOME

The patient was kept overnight and discharged the next day. The Pounce™ Thrombectomy System aided in the removal of acute and organized thrombus in one pass.



Surmodics, Inc.
7905 Golden Triangle Drive
Suite 190
Eden Prairie, MN 55344 USA
Toll Free: 888-626-8501
Phone: 952-500-7400
www.pouncesystem.com

Caution: Federal (US) law restricts this device to sale by or on the order of a physician. Please refer to Instructions for Use for indications, contraindications, warnings, and precautions.

SURMODICS, POUNCE, and the SURMODICS and POUNCE logos are trademarks of Surmodics Inc. and/or its affiliates. Third-party trademarks are the property of their respective owners.

All images used with permission of author. ©2023 Surmodics, Inc. All rights reserved. SRDX-PTS-908 A